

# REDUCING RECOVERY TIME WHILE INCREASING PROFILE IMPROVEMENT: A NOVEL DEEP PULSE FRACTIONAL CO<sub>2</sub> LASER COMBINED WITH A RADIO-FREQUENCY SYSTEM

*Redução do Período de Recuperação e Melhora de Resultados Utilizando um Novo Laser Fracionado de Co<sub>2</sub> com Radio-frequencia*

<sup>1</sup>Department of Dermatological Sciences.

<sup>2</sup>Photobiolab Research Unit University of Florence.

P. Bonan<sup>1</sup>  
G. Cannarozzo<sup>1</sup>  
M. Troiano<sup>1</sup>  
C. Morini<sup>1</sup>  
D. Fortuna<sup>2</sup>  
P. Campolmi<sup>1</sup>

## Abstract

Minimally ablative or sub-ablative lasers, such as fractional CO<sub>2</sub> lasers, have been developed in an attempt to achieve the clinical results observed with traditional ablative lasers but with minimal side effects. Despite being an ablative laser, this fractional delivery system is able to produce a fractional supply of the beam of light. Moreover, the generating of fractional ablation of the tissue through the development of microscopic vertical columns surrounded by spared areas of epidermis and dermis, ensures rapid wound healing and minimum downtime. The new PSD (Pulse Shape Design) technology allows for selecting different pulse waveforms in order to meet the needs of all skin conditions, each optimized and adapted for correct use with cold superficial fine ablation, minimally deeper thermal ablation or more volumetric thermal ablation. With this system, the deep ablation and thermal stimulation help reduce superficial erythema and oedema, lowering the operating and post-operative pain levels and preserving the therapeutic effects in the reticular derma, thus producing rapid and high-quality results. The simultaneous synchronized delivery of a RF current to the deeper layer of the skin completes the therapeutic scenario, ensuring an effective skin tightening effect over the entire area treated. We describe the preliminary results observed in the treatment of wrinkles and acne scars using this new laser technology.

**Descriptors:** Fractional CO<sub>2</sub> Laser, Laser, Radio-frequency, tissue repair

## Resumo

Os lasers minimamente ablativos ou sub-ablativos, tais como o CO<sub>2</sub> fracionado, foram desenvolvidos como uma tentativa de se atingir os resultados clínicos observados com os lasers ablativos, porém com mínimos efeitos colaterais. Apesar de ser um laser ablativo, este sistema de emissão fracionada é capaz de produzir uma fonte fracionada do raio de luz. Além disso, a geração da ablação fracionada no tecido através do desenvolvimento de colunas verticais microscópicas cercadas por áreas preservadas de epiderme e derme, asseguram uma rápida cicatrização, com um mínimo tempo para recuperação. A nova tecnologia PSD (Pulse Shape Design) permite selecionar diferentes formas de onda pulsada para adaptar-se às necessidades de todos os tipos de pele, todas otimizadas e adaptadas para o uso correto com ablação superficial fria, ablação térmica minimamente profunda ou ablação térmica de maior volume. Com este sistema, a ablação profunda e a estimulação térmica ajudam a reduzir o eritema superficial e o edema, diminuindo os níveis de dor operatória e pós-operatória e preservando os efeitos terapêuticos na derme reticular, produzindo ainda resultados rápidos e de alta qualidade. Esta emissão simultânea e sincronizada de uma corrente de radiofrequência à camada profunda da pele completa o cenário terapêutico, assegurando uma contração cutânea efetiva em toda a área tratada. Descrevemos os resultados preliminares observados no tratamento de ríndes e cicatrizes de acne usando esta nova tecnologia laser.

**Descritores:** Laser Fracionado de CO<sub>2</sub>, Rádio-frequência, Reparação de tecidos

## Endereço:

Donatello Day Surgery Clinic - Via di Careggi 38 - 50139 Florence Italy.



## INTRODUCTION

Fractional resurfacing has become one of the most popular dermatologic surgical laser procedures<sup>1</sup>. In our extensive experience with lasers, the ablative resurfacing CO<sub>2</sub> laser has always been considered the gold standard for treating wrinkles, photoaging damage, and acne scars. However, this method also entails possible post-op infectious complications (bacterial and viral infections) and uncomfortable side effects (persistent erythema, skin alterations, post-inflammatory pigmentation and possible atrophic scarring). Therefore, due to the complete vaporization of the epidermis and part of the dermis, as well as the associated risks and prolonged healing time, its use has been limited<sup>2</sup>.

The latest laser resurfacing techniques now exploit the various synergies offered by the different techniques.

The development of medical laser systems now guarantees dedicated and customized delivery pulse wavelengths, aimed at treating all the various skin pathologies in a completely safe, effective and accurate manner<sup>2</sup>.

In the case of skin rejuvenation, the last generation CO<sub>2</sub> medical lasers are now providing patients with constantly reduced downtimes and excellent skin tightening results<sup>3</sup>.

In our experience with fractional CO<sub>2</sub> lasers, it is now possible to treat patients with various degrees of photo damage with reduced healing times and less operative and post-op discomfort<sup>4</sup>.

This technique has proved its effectiveness on wrinkles, acne scars and sun spots, due to an enhanced neocollagenogenesis process with the new generation pulse waveforms and a synchronized bipolar radiofrequency current for enhancing skin tightening, elasticity and smoothness<sup>5</sup>.

This method can be considered a valid response to the growing technological demand for high-quality

results vs. continuously reduced healing times.

Consequently, over the last 10 years the rapid development of medical laser systems has made it possible to perform safer and more effective treatments on numerous injuries, even the most complex and severe. This has also been possible thanks to a more in-depth understanding of laser-tissue interactions and anti-aging technologies, leading to the production of “clinically more flexible” systems, especially in dermatology.

The CO<sub>2</sub> systems are now called on to provide additional answers to the increasing demand for reduced downtime coupled with excellent skin tightening<sup>3</sup>. To date, CO<sub>2</sub> laser technology has been developed to improve fine lines, skin texture and tone, now this new challenge also includes significant skin tightening<sup>3</sup>.

The optimal clinical performance currently obtained with this new fractional laser system, which combines laser energy with bipolar radiofrequency, has enabled us to achieve excellent results.

The characteristics of the skin of patients who respond most positively to this laser technique are: yellow/grayish skin colour, the presence of superficial pigmentation, fine lines, wrinkles, medium skin roughness, enlarged pores, impaired skin texture, and various kinds of acne scars<sup>6</sup>. Moreover, this treatment seems to be particularly indicated and effective for the treatment of delicate areas such as the periocular area<sup>7</sup>.

## CASE REPORT

Nine female patients with Fitzpatrick skin types II-III, underwent 1-3 subsequent treatments with CO<sub>2</sub> plus RF. The age of the patients enrolled in our study was between 30 and 66 years old. Before starting therapy written informed consent was obtained

from all patients after clear medical explanations.

The inclusion criteria for this technique included: no topical exfoliating treatments for at least two months, no photosensitizers drugs or oral retinoids for at least eight months, no surgical treatments or therapies and local injections for at least eight months, no photorejuvenation treatments with other sources or treatments exploiting photodynamic therapy with ALA for at least one year. We excluded patients with a positive history for keloid or collagen formation.

Four patients enrolled in the study had acne scars while five had different degrees of photoaging in sun exposed areas.

The clinical symptoms observed in most of our patients included atrophic acne scars, fine and deep wrinkles, dyschromia, elastosis, texture alterations and actinic keratosis.

Since laser treatment may induce the onset of herpes simplex in some patients, an antiviral prophylaxis was prescribed before treatment.

In order to ensure better patient compliance, a topical anaesthetic cream (applied about 15-20 minutes prior to treatment) or a light dynamic cooling (cool shot) system might be endorsed.

In addition, digital clinical images were also obtained.

We used a CO<sub>2</sub> 1060-nm laser (DEKA, M.E.L.A, Florence) equipped with a fractional scanner system (SmartXide2, DEKA, M.E.L.A, Florence) capable of producing fractional micro-ablation and heat diffusion of the tissue. The parameters used were: power, 8-14 watts; spacing, 500-1000 µm; stack, 2-4, pulse length, 600-1000 milliseconds; scanning square (15 mm x15 mm) and RF20-40 watts, 2-3 sec.

## RESULTS

Each patient underwent 1-3 treatment sessions spaced 2 months apart.



80% of patients reported a mild burning sensation during treatment but immediate good clinical appearance. Immediately after surgery several patients suffered slight, transient episodes of erythema and oedema (more evident with treatment of the eye area).

At the end of treatment, compression with gauze soaked in saline solution was applied for twenty minutes followed by an application of cold emollient cream. These medications were also recommended for home use by patients. Small scabs showing a colour change (to brown) appeared on the treated skin 3 days after treatment and fell off after one week, leaving a furfural desquamation.

The areas treated included the area around the eyes, forehead, around the mouth, chin and cheeks.

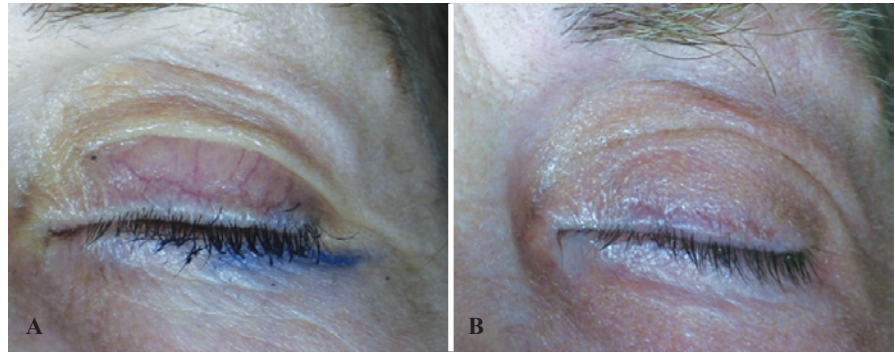
In all cases there was a significant improvement in wrinkles and texture and the neocollagenesis induced by laser treatment also reduced the signs of acne scars while reducing recovery time (Figures 1-3).

## DISCUSSION

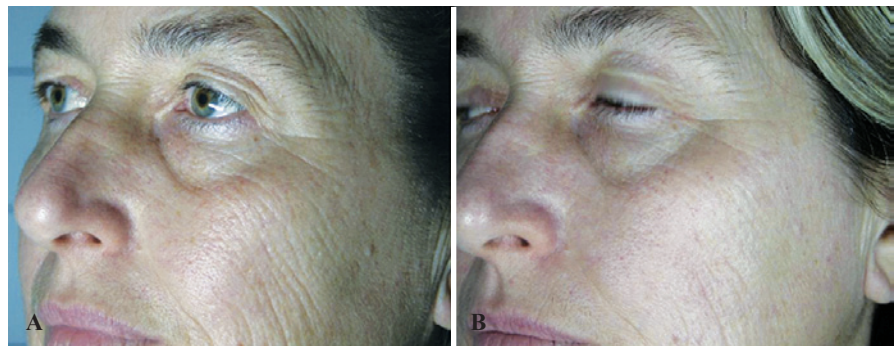The demand for the excellent clinical results of an ablative laser such as CO<sub>2</sub>, with a lower risk of side effects associated with post-treatment and a shorter downtime, has led to the development of a laser minimally-ablative fractional with bipolar RF.

This new generation fractionated CO<sub>2</sub> laser is equipped with a fractional scanning system (HiScanDOT/RF) that creates micro-columns of thermal damage surrounded by healthy tissue<sup>8</sup>.

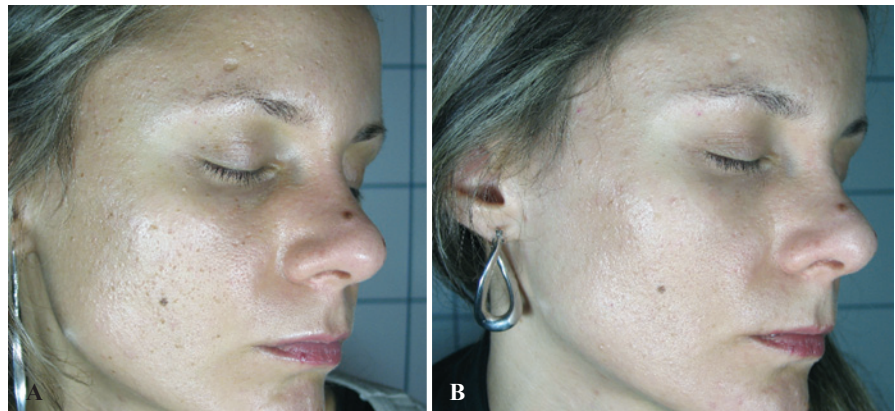
These columns of light are able to provide authentic vertical scaling of the epidermis, with a true micro-ablation of the epidermis and a variable micro thermal zones (MTZ) produced by the controlled heat released by the selected pulse (usually S-Pulse for increased thermal release and D-Pulse for greater



**Figure 1 - A-B** Eyelids skin thitening before and 30 days after the treatment (FCO2/RF: 8 watts, Dpulse, Stack 2, DwellTime 600  $\mu$ sec, Space 700  $\mu$ m; RF: 2 W, 1,5 sec).



**Figure 2 - A-B** Severe wrinkles of the cheek before and after the treatment (FCO2/RF: 12 watts, Dpulse, Stack 3, DwellTime 800  $\mu$ sec, Space 800  $\mu$ m; RF: 3 W, 2,5 sec).



**Figure 3 - A-B** Ice-peak acne scars before and after the treatment (FCO2/RF: 10 watts, Dpulse, Stack 3, Dwell-Time 600  $\mu$ sec, Space 800  $\mu$ m; RF: 3 W, 2 sec).

thermal control with a reduced action on the dermal layers in the case of skin laxity) induce an immediate shrinkage of the tissues, promoting stimulation of growth factors and wound repair proteins that generate and reorganise new collagen fibres<sup>4</sup>. The areas of healthy tissue in between the MTZs,

allow for faster tissue repair and an enhanced overall stimulation of the dermal components<sup>9</sup>.

The great variety of combinations among the MTZs, pulse duration (Dwell time) and Power (measured in W) make this laser the gold standard for treating all skin types in a com-

pletely safe manner<sup>10</sup>. The variety of waveform pulses possible with this new CO<sub>2</sub> Laser and RF unit also makes this unit an effective tool for reducing healing times, post-op pain and side effects. At the same time, the system delivers a bipolar radiofrequency current that stimulates the tissue from the inside up to the reticular dermis, exploiting lower energy levels in order to prevent undesirable skin damage.

Normally, only 10% of the Radio Frequency current penetrates the deeper skin layers as a result of the physiological impedance that this current encounters along the way.

A controlled laser emission delivery reduces the resistance of the epidermis and dermis due to the Hyperemia of the fine superficial vessels. This means that the RF current (+40% vs. standard techniques) can easily penetrate deeper into the reticular dermis, generating a more homogeneous bio-stimulation distribution from the inside thanks to the deeper generation of homogeneous and constant

volumetric heat. In this way the tissue between the MTZs is also tightened with excellent visible results. With this new method a far more significant reduction in superficial erythema has also been observed at the 2 to 3-day follow-up compared to the standard CO<sub>2</sub> Laser ablation.

## CONCLUSIONS

This new fractional technique is highly acclaimed by everyone involved in skin rejuvenation of the face and neck.

This combined/synchronized system has proved its effectiveness on wrinkles and acne scars, with progressive enhancement of skin elasticity, thanks to the fibroblast activation and neocollagenogenesis, with a great improvement of smoothness and reduction of roughness of the skin in addition to the overall volumetric skin tightening<sup>3</sup>.

The healing time (disappearance of erythema) was between 3 and 7 days

in almost all patients, and the duration of erythema did not exceed 5 days in any patients. No persistent oedema was observed.

The equipment which combines laser energy with bipolar radiofrequency system ensures a significant reduction in side effects and post-op complications (bacterial infection, atrophic scars, hypopigmentation, post-inflammatory hyperpigmentation) compared to standard ablative treatments. Appropriate therapy should however be implemented for preventing the possibility of pre- and post- treatment herpes complications.

This synergic action allows for reducing the overall downtime and provides an excellent skin tightening effect<sup>3</sup>. It is particularly indicated and efficacious on very delicate areas, such as the neck, throat and hands which are difficult to treat with traditional methods, or in cases of hypertrophic scars, ice-pick acne scars and whenever the downtime must be reduced.

## REFERENCES

1. Jih MH, Kimyai-Asadi A. Fractional photothermolysis: a review and update. *Semin Cutan Med Surg* 2008;27:63-71.
2. Tarijian AL, Goldberg DJ. Fractional ablative laser skin resurfacing: a review. *J Cosmet laser ther*. 2011 Dec;13(6):262-4
3. Rahman Z, MacFalls H, Jiang K et al. Fractional Deep Dermal Ablation induces tissue tightening. *Lasers Surg Med* 2009;41:78-86
4. Prignano F, Campolmi P, Bonan P, Ricceri F, Cannarozzo G, Troiano M, Lotti T. Fractional CO<sub>2</sub> laser: a novel therapeutic device upon photobiomodulation of tissue remodeling and cytokine pathway of tissue repair. *Dermatol Ther*. 2009 Nov;22 Suppl 1:S8-15.
5. Prignano F, Bonciani D, Campolmi P, Cannarozzo G, Bonan P, Lotti T. A study of fractional CO<sub>2</sub> laser resurfacing: the best fluences through a clinical, histological, and ultrastructural evaluation. *J Cosmet Dermatol*. 2011 Sep;10(3):210-6
6. Peterson JD, Palm MD, Kiripolsky MG, Guiha IC, Goldman MP Evaluation of the Effect of Fractional Laser with Radiofrequency and Fractionated Radiofrequency on the Improvement of Acne Scars. *Dermatol Surg*. 2011 Aug 11
7. Bonan P, Campolmi P, Cannarozzo G., Bruscinò N., Bassi A., Betti S., Lotti T. Eyelid skin tightening: a novel Niche for fractional CO<sub>2</sub> rejuvenation. *J EADV*
8. Hantash BM, Bedi VP, Kapadia B et al. In vivo histological evaluation of a novel ablative fractional resurfacing device. *Lasers Surg Med* 2007;39:14-18.
9. Bonan P, Campolmi P, cannarozzo G, Bruscinò N, Bassi A, Betti S, Troiano M; Bonciani D, Prignano F, Pavone P, Lotti T. Photorejuvenation with dermo-epidermal optical thermolysis: Several evaluating systems. Abstract from EADV congress, Lisbon September 2011
10. Bonan P, Fortuna D, Bruscinò N, Cannarozzo G, Campolmi P. Does pulse shape influence fractional CO<sub>2</sub> treatment? Continental meeting, Cannes September 2011.

